

Ponseti clubfoot management: Experience with the Steenbeek foot abduction brace

Paul Mang'oli MBChB¹, Joseph Theuri MBChB MMed²,
Tobias Kollmann MD PhD³, Noni E MacDonald MD MSc FRCPC⁴

Clubfoot is one of the most common congenital deformities, with an incidence of one in 1000 live births worldwide. In Kenya, approximately 1200 infants are born with clubfoot every year. Left untreated, clubfoot leads to painful, disabling deformity and social stigmatization. Bracing is an integral part of the internationally accepted standard of care, and the Ponseti method of clubfoot management with compliance with bracing is considered to be the key to a successful outcome (1). This has brought the type of brace under scrutiny, with newer 'child-friendly' braces recommended over the traditional Dennis Brown brace (Figure 1), which has been associated with high rates of noncompliance. However, these child-friendly braces are expensive (USD\$300) and out of reach for most families of affected children in Kenya and other developing countries. The Steenbeek foot abduction brace (SFAB) is made locally in Kenya at a cost of <USD\$10 (Figure 2). The SFAB has been in use since the inception of the Clubfoot Care for Kenya (CCK) program in 2005. Therefore, we performed a study investigating SFAB acceptance, tolerability, compliance, complications and outcomes in the CCK program.

METHODS

The present cross-sectional study was performed between January and June 2014, in four health institutions affiliated with the CCK program: CURE International Children's Hospital, Kijabe, Kenya; Association for the Physically Disabled Persons of Kenya (APDK), Nairobi, Kenya; APDK, Kisumu, Kenya; and Moi Teaching and Referral Hospital, Eldoret, Kenya. These institutions provide CCK services across Kenya for patients in both urban and rural settings, each accounting for approximately 50% of the clubfoot burden in their area.

Children on braces are typically followed-up initially monthly, then every three months and, eventually, every six months until four years of age; thus, all children in the CCK program should




Figure 1) The traditional Dennis Brown foot abduction brace

have been seen over the study period. Because the present study was an observational review of information routinely collected at hospital visits for clubfoot care rather than an intervention study, permission to perform the study was formally obtained from the heads of the respective health care institutions. Parents of infants with clubfoot were invited to participate in the study at the time of their scheduled clubfoot clinic appointments. Participation was voluntary after informed consent. Inclusion criteria consisted of registered CCK members who had used an SFAB for ≥ 6 months, and were willing to participate and consent.

A questionnaire was used to systematically collect data from the participants. Tolerability was assessed as absence of visible discomfort of the child when the brace was applied, and compliance as consistent brace use for ≥ 6 months. Complications were defined as any skin lesion to the lower limb resulting from brace use. Outcome was defined as progress observed in the correction of the foot deformity compared with the previous two visits. Data were compiled and analyzed in terms of sex, age, duration of brace use and complications. These data were then compared with a previous study that compared the traditional Dennis Brown brace with the newer, but expensive, child-friendly braces (2).

RESULTS

All parents who were approached were willing to participate in the study, and 223 patients (361 club feet) were enrolled. The mean age at enrollment was 23 months, with a male-to-female ratio of 2:1. The mean duration of SFAB wear was 18 months (range six to 28 months). No visible discomfort was noted in 93.5% of children while using the SFAB. Noncompliance with SFAB use was reported to be 15% (33 of 223 patients), compared with 41% (21 of 51) of patients using a traditional brace and 7.1% (two of 28) of patients using the newer child-friendly brace in the previous study (2). Reported complications with the SFAB were 5% (11 of 223), in the form of skin bruising and pressure sores on the feet,

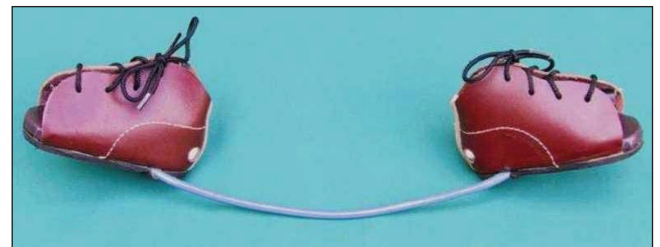


Figure 2) The Steenbeek foot abduction brace

¹Orthopaedic Surgery, College of Surgeons of East, Central and Southern Africa; ²Orthopaedic Surgery, CURE International Children's Hospital, Kenya; ³Microresearch and University of British Columbia, Vancouver, British Columbia; ⁴Microresearch and Dalhousie University, Halifax, Nova Scotia
Correspondence: Dr Noni E MacDonald, Department of Paediatrics, Dalhousie University, IWK Health Center, 5850/5980 University Avenue, Halifax, Nova Scotia B3K 6R8. Telephone 902-470-8799, e-mail noni.macdonald@dal.ca
Accepted for publication October 23, 2014

compared with 23.5% (12 of 51) in the traditional brace and 7.1% (two of 28) with the newer brace reported by Chen et al (2). Of the children using the SFAB, 94% (179 of 190) who reported good compliance showed improvement in foot deformity correction compared with previous visits, compared with 53% (17 of 33) who had been noncompliant with the SFAB.

CONCLUSION

The affordable, locally made SFAB was well tolerated, with compliance appearing to be remarkably better than with the traditional Dennis Brown brace, but perhaps marginally inferior to the newer, but more expensive, child-friendly brace types. The interim outcomes with the use of the SFAB in foot correction were excellent.

IMPLICATIONS

The low-cost SFAB, shown to have high efficacy and minimal complications, should stimulate all ministries of health in developing countries to incorporate clubfoot treatment into mainstream services, with provision of these appliances to all affected infants.

ACKNOWLEDGEMENT: The authors thank Mr Gideon Muga, National Director, APDK, for funding the study; the heads of the institutions for allowing the authors to obtain data from their patients; MicroResearch, for providing advice and technical support in reviewing and reporting the findings; and E Kioko, P Kinyanjui, I Gachohi, I Otieno, K Njeri and F Waweru, for their support toward collecting and compiling the data.

DISCLOSURES: The content of this article is the sole work of the authors. No benefits of any form have been derived from any commercial party related directly or indirectly to the subject matter of this article.

REFERENCES

1. Thacker MM, Scher DM, Sala DA, Bosse HJ, Feldman DS, Lehman WB. Use of the foot abduction orthosis following Ponseti casts: Is it essential? *J Pediatr Orthop* 2004;225-8.
2. Chen RC, Gordon JE, Luhmann SJ, Schoenecker PL, Dobbs MB. A new dynamic foot abduction orthosis for clubfoot treatment. *J Pediatr Orthop* 2007;27:522-8.